

Endoscopic Tympanoplasty Using Nasal Septal Cartilage Allograft

N. Ahilasamy¹ · Badra Shanti¹ · Sivaprakasam Rajasekaran¹

Received: 9 July 2016 / Accepted: 9 January 2017 / Published online: 13 January 2017
© Association of Otolaryngologists of India 2017

Abstract The purpose of the study was to analyze the morphological and functional outcomes in a series of 60 patients for whom Type I tympanoplasty was done using alcohol preserved nasal septal cartilage allograft through endoscopic permeatal route. The study was a prospective, interventional (surgical) study of 60 patients between October 2012 and September 2014. Patients were operated using 0°, 4 mm, 18 cm long Hopkin's rod endoscope through permeatal route. 70% ethyl alcohol preserved allogeneic nasal septal cartilage with thickness of around 0.5 mm was used for grafting. At the end of 6 months, final assessment of morphological outcome i.e. intact tympanic membrane and functional outcome i.e. reduction in Air Bone gap, was done. At the end of 6 months, 57 patients (95%) had intact tympanic membrane. Mean ABG in postoperative patients was 11.83 dB. The operative time taken in 42 patients (70%) was 30–45 min. 42 patients (70%) returned to normal activity in 3–5 days. Endoscopic cartilage tympanoplasty using allogenic nasal septal cartilage can be safely and effectively used for Type I tympanoplasty with good anatomical and audiological results with benefits of reduced operating time, morbidity, pain and 'No scar'.

Keywords Myringoplasty · Endoscopic tympanoplasty · Cartilage tympanoplasty · Nasal septal cartilage · Allograft

Introduction

Different types of graft materials have been tried to repair the tympanic membrane (TM) since tympanoplasty was introduced by Wullstein [1] and Zoellner [2]. These include temporalis fascia, fat, cartilage, perichondria, periostia, dura and vein [3]. Temporalis fascia remains the most commonly used material for tympanic membrane reconstruction, with a success rate of 93–97% in primary tympanoplasties [4]. Even in hands of experts, failures occur as fascia and perichondrium have been shown to undergo atrophy and subsequent failure in the postoperative period, regardless of placement technique [5–8]. These observations have revived the interest in cartilage as grafting material, as cartilage is more compliant and stiff preventing the retraction and resorption of neotympanic membrane in postoperative period. There has been an increase in the use of cartilage tympanoplasty with surgeons reporting improved outcomes when compared with temporalis fascia used alone [9]. It has been shown in both experimental and clinical studies that cartilage is well tolerated by the middle ear, and long-term survival is the norm [10–14].

Cartilage was first introduced in middle ear surgery in [15] and has been described for the limited management of retraction pocket [16–21] and more recently, for the reconstruction of the tympanic membrane in cases of recurrent perforation, with encouraging results [8, 22, 23]. Despite the thickness of the grafts, the hearing results appear to be good [8, 22–26]. In our study, we used 70%

✉ N. Ahilasamy
nahilasamy@yahoo.com

¹ Department of ENT and HNS, Dr. Kamakshi Memorial Hospital, #1, Radial Road, Pallikaranai, Chennai, Tamil Nadu 600044, India

ethyl alcohol preserved nasal septal cartilage allograft as graft for tympanoplasty.

Materials and Methods

The present study was conducted in the department of otorhinolaryngology, Dr Kamakshi Memorial Hospital, Chennai from October 2012 to September 2014. All patients presenting in ENT outpatient department with complains of ear discharge and decreased hearing were examined. In a period of 2 years, 110 patients were screened but based on inclusion and exclusion criteria, 60 patients were selected for the study.

Inclusion Criteria

Patients of both sexes equal to and more than 10 years of age.

- Small to large central perforations
- Dry perforations
- Patient willing for surgery and regular follow up

Exclusion Criteria

- Subtotal, total perforation
- Patients with unsafe ear
- Active discharging ear
- Otitis externa, otomycosis
- Uncontrolled diabetes mellitus
- Patients having upper respiratory tract infection at the time of surgery
- Patients not willing for study or regular follow up

Size of perforation was recorded according to the number of quadrants involved. Tuning fork tests was done to determine the degree and type of hearing loss. Pure tone audiometry was done according to American speech and hearing association (ASHA) method.

All the patients were operated using zero degree, 4 mm, 18 cm long Hopkin's rod endoscope through permeal route. 70% ethyl alcohol preserved allogenuous nasal septal cartilage with thickness of around 0.5 mm was used for grafting.

Technique

Part preparation was not required. Patients under sixteen 16 years of age were operated under general anesthesia. For patients of age 16 years and above, we preferred to operate under local anesthesia. Patient placed in supine position with head turned to opposite side. Local

infiltration of 2% Lignocaine solution with 1:100,000 adrenaline was used for all patients irrespective of local or general anesthesia to have adequate local vasoconstriction and hydro dissection of planes. 0.5 ml of anesthetic is infiltrated in each four quadrants (at 3, 6, 9, 12) O'clock positions, postaural region and incisura terminalis.

Endoscope was introduced in the external auditory canal. The edges of the perforation were freshened with a sickle knife. Canal incision is made 8 mm lateral to the tympanic annulus from 1 to 4o'clock for right ear and 11–8 o'clock for left ear (270° elevation) with a circular knife. The tympanomeatal flap is elevated and raised superiorly. Ossicular mobility is checked. A single piece of 70% ethyl alcohol preserved allogenuous nasal septal cartilage was taken and sliced to approximately 0.5 mm thick with dimensions of around 2 cm width, 1 cm length and 0.5 mm thickness for grafting (Fig. 1).

Diameter of cartilage was kept slightly more than perforation. The cartilage graft was placed by underlay technique above handle of malleus (Fig. 2).

Tympanomeatal flap is replaced and gelfoam packed in the canal. All patients were followed up for 6 months. At the end of 6 months, final assessment of morphological outcome i.e. intact tympanic membrane was done by visualization with 0° endoscope in outpatient department (Fig. 3).

Functional outcome is measured with pure tone audiometry at 6 months and was compared with preoperative pure tone audiometry records. An intact mobile tympanic membrane at the end of 6 months with closure of air-bone gap to less than or equal to 20 dB is taken as a successful outcome.

Results

The male to female ratio in our study was 4:1 (48 males and 12 females). The age distribution ranged from 12 to 57 years and maximum patients were in third decade. Most of the patients (3.33%) had medium size perforation. 50% patients had right side perforation and 4 patients (7%) had bilateral perforation.

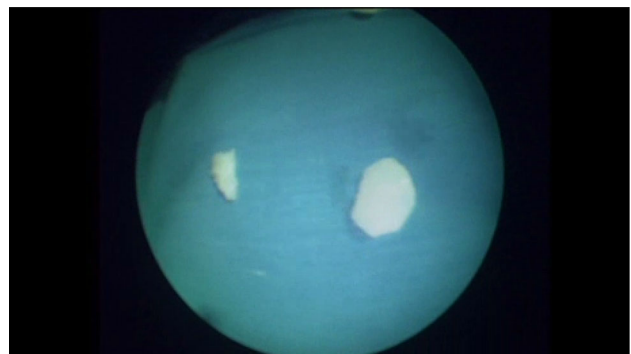


Fig. 1 Nasal septal cartilage allograft

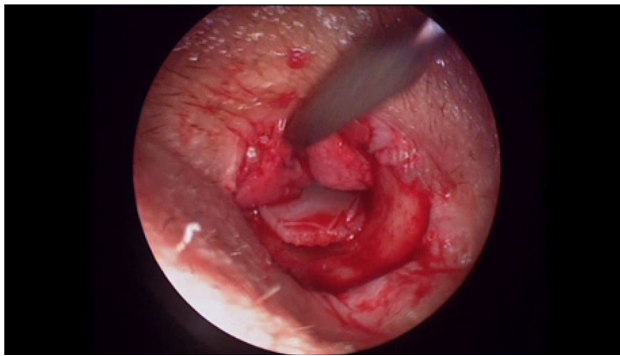


Fig. 2 Allograft placed in middle ear by underlay technique

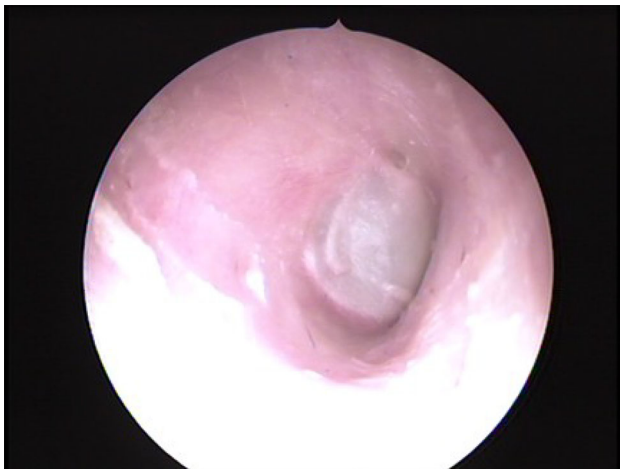

Fig. 3 Six months post-operative result showing intact tympanic membrane

Table 1 Operative time

Operative time (minutes)	Number of cases	Percentage (%)
30–45 min	42	70
45–60 min	18	30
0–90 min	0	–

The operative time taken by most of the patients (70%), was 30–45 min (Table 1). In rest of the patients (30%), surgery got over by 60 min. None of the surgery took more than 1 h.

42 (70%) patients returned to their normal activity within 3–5 days (Table 2). 4 patients (6.67%) returned to normal activity within 3 days of surgery. 14 patients (23.33%) returned to normal activity in 8 days.

At the end of 6 months, 57 patients (95%) had intact tympanic membrane and 3 patients (5%) had residual perforation (Table 3).

The mean ABG in postoperative patients was 11.83 dB. 54 patients (90%) had ABG less than 20 dB (Table 4).

Table 2 Return to normal activity

Return to normal activity (days)	Number of cases	Percentage (%)
<3 days	4	6.67
3–5 days	42	70
6–8 days	14	23.33

Table 3 Morphological outcome

Morphological outcome (at the end of 6 months)	Number of cases	Percentage (%)
Intact tympanic membrane	57	95
Residual perforation	3	5

Table 4 Functional outcome (Pure tone audiometry results)

Average conductive hearing loss (dB)	Preoperative	Percentage (%)	Postoperative	Percentage (%)
0–10	0	–	25	41.67
11–20	22	36.67	29	48.33
21–30	34	56.67	6	10
31–40	4	6.67	0	–

Discussion

Otologists have been venturing for newer graft materials in view of failures of temporalis fascia in tympanoplasty. Causes of tympanoplasty failure using a temporalis fascia graft include atelectasis, tympanosclerosis, large perforation, pathology of malleus handle, anterior perforation, perforation during surgery, tobacco smoke exposure and bilateral disease [27, 28]. Since the temporalis muscle fascia is composed of irregularly arranged elastic fibers and fibrous connective tissue, the postoperative dimensions of the graft are usually unpredictable [29]. A more rigid, more compliant and retraction resistant graft material is being searched.

Although cartilage has been used for Ossiculoplasty for almost half a century, renewal of interest for using as a graft in tympanoplasty is more apparent in last decade only. The rigidity and stiffness of cartilage resists retraction of tympanic membrane resulting in better morphological outcome. However, various studies have shown that it does not dampen the acoustic transfer of sound. Thus, hearing improvement is not adversely affected and is comparable with that of temporalis muscle fascia graft. A publication comparing perichondrium and cartilage in revision Type I tympanoplasty showed no difference in hearing between the two groups, with both exhibiting ABG of less than 10 dB [24]. Another comparison study was performed by

Gerber et al. [25] in which cartilage was compared to fascia in frequency specific manner, and again no significant difference was seen with graft uptake of 100%. Duckert et al. [8] reported 97% graft take up with cartilage and excellent hearing results [23]. Milewski, reporting on his large series of cartilage tympanoplasties, of which 197 were Type I, achieved drum closure in 92%, with an average ABG less than 30 dB, in 92%. Amadee et al. [22] reported on 52 cases of cartilage tympanoplasty of which 18% were Type I in which post-operative ABG was 4 dB, with TM closure in all patients. Adkins reported 55 cases of cartilage tympanoplasties for retraction [21] with post op ABG of less than 10 dB, and TM closure in all patients. In our study, 95% patients had positive morphological outcome and 90% patients had ABG < 20 dB, which is comparable with temporalis fascia graft tympanoplasty. In a RCT by Cabra and Monoux [30], showed statistically significant better morphological results with cartilage tympanoplasty, compared with temporalis fascia tympanoplasty and no statically significant difference in hearing levels in these 2 groups. Mirko Tos [31] has proposed 23 cartilage tympanoplasty methods to reconstruct the eardrum.

In our study, we have used a single cartilage disc of 0.5 mm and placed it by underlay technique. A study using the laser Doppler interferometer and cadaver cartilage conducted by Zahnert et al. [32] demonstrated that ideal acoustic thickness of cartilage should be about 0.5 mm, compared to the full thickness harvest of 0.7–1 mm.

Allograft is tissue transplanted between genetically non-identical members of the same species e.g. cadaveric tympanic membrane graft, septal cartilage graft. Various methods have been used for preservation of graft materials like 70% ethyl alcohol, 0.02% aqueous cialit, 4% buffered formaldehyde fixation and 0.5% buffered formaldehyde preservation etc.

Allogeneous nasal septal cartilage was introduced by Jansen (1963) for Ossiculoplasty [28]. Various studies have been conducted to study the morphology of alcohol preserved nasal septal cartilage grafts in middle ear. Kerr et al. [33] studied nasal septal cartilage allografts (alcohol preserved) for middle ear re-construction and concluded that in most of the grafts, morphology of the graft is maintained. [34] did a histological study and found no obvious resorption of cartilage grafts removed from middle ear [34]. In a study by Iwanaga [35], the fate of homologous nasal septal cartilage implanted in middle ear was studied by means of enzyme digestion. Homologous cartilages showed depletion of mucopolysaccharides but hyaluronic acid and collagen remained intact. It was concluded that homologous nasal septal cartilages could be used in tympanoplasty.

According to Froot Ko [36] the immune rejection responses to allograft tissue across major histocompatibility barriers are muted in deep external auditory canal and middle ear. These sites are immunologically privileged sites, favorable for graft acceptance. Preservation of otological allograft makes them less susceptible for rejection, by altering the molecular configuration of antigenic determinants. This appears to diminish the graft's ability to immunize the recipient, but does not alter their specificity.

Endoscopes provide wide angle, panoramic and magnified view of the whole tympanic membrane. Endoscopes can easily negotiate through external auditory canal and provide uninterrupted image whereas with microscope [29], canal stenosis and bony overhangs can obscure the area of interest and may require canalplasty and canal wall curettage, which can prolong the duration of the surgery. Permeatal route with endoscope avoids the post aural scar, needs less tissue dissection resulting in reduced pain and morbidity. Use of preserved homograft reduced our operative time considerably. It avoids the time taken for harvesting temporalis fascia graft.

Conclusion

With improving technologies, endoscopic cartilage tympanoplasty is an effective alternative of microscopic tympanoplasty. Allograft nasal septal cartilage can be safely and effectively used for Type I tympanoplasty with benefits of reduced operating time, morbidity, pain and better cosmesis with no scar.

Compliance with Ethical Standards

Conflict of interests All authors declare that, we have no conflicts of interest.

References

1. Wullstein HL (1953) Functional operations in the middle ear with split thickness skin graft. *Arch Otorhinolaryngol* 161:422–435
2. Zoellner F (1955) The principles of plastic surgery of the sound conducting apparatus. *J Laryngol Otol* 69:567–569
3. Heerman H (1960) Tympanic membrane plastic with temporal fascia. *Hals-Naser-Ohren* 9:136–139
4. Sheehy JL, Anderson RG (1980) Myringoplasty. A review of 472 cases. *Ann Otol Rhinol Laryngol* 89:331–334
5. Buckingham RA (1992) Fascia and perichondrium atrophy in tympanoplasty and recurrent middle ear atelectasis. *Ann Otol Rhinol Laryngol* 101:755–758
6. Goodhill (1967) Tragal perichondrium and cartilage in tympanoplasty. *Arch Otolaryngol* 85:35–47
7. Glasscock ME, Jackson CG, Nissen AJ, Schwaber MK (1982) Postauricular undersurface tympanic membrane grafting: a follow-up report. *Laryngoscope* 92:718–727

8. Milewski C (1993) Composite graft tympanoplasty in the treatment of ears with advanced middle ear pathology. *Laryngoscope* 103:1352–1356
9. Onal K, Arslanoglu S, Oncel S et al (2011) Perichondrium/cartilage island flap and temporalis muscle fascia in Type I tympanoplasty. *J Otolaryngol Head Neck Surg* 40:295–299
10. Loeb L (1926) Auto transplantation and homotransplantation of cartilage in the guinea pig. *Am J Pathol* 2:111–122
11. Peer LA (1939) The fate of living and dead cartilage transplanted in humans. *Surg Gynecol Obstet* 68:603–610
12. Levinson RM (1987) Cartilage-perichondrial composite graft tympanoplasty in the treatment of posterior marginal and attic retraction pockets. *Laryngoscope* 97:1069–1074
13. Yamamoto E, Iwanaga M, Fukumoto M (1988) Histologic study of homograft cartilage implanted in the middle ear. *Otolaryngol Head Neck Surg* 98:546–551
14. Hamed M, Samir HF, El Bigermy M (1999) Fate of cartilage material used in middle ear surgery light and electron microscopy study. *Auris Nasus Larynx* 26:257–262
15. Utech H (1959) Ueber diagnostische und therapeutische Möglichkeiten der Tympanotomie bei Schalleitungsstörungen. *Laryngol Rhinol* 38:212–221
16. Goodhill V (1967) Tragal perichondrium and cartilage in tympanoplasty. *Arch Otolaryngol* 85:480–491
17. Heermann H, Heermann J (1964) Endaurale Chirurgie/Endaural Surgery. Urban & Schwarzenberg, Munich
18. Sheehy JL (1985) Surgery of chronic otitis media. In: English G (ed) *Otolaryngology*, vol 1, revised edn. Harper and Row, Philadelphia, pp 1–86
19. Glasscock ME, Hart MJ (1992) Surgical treatment of the atelectatic ear. In: Friedman M (ed) *Operative techniques in otolaryngology-head neck surgery*. WB Saunders, Philadelphia, pp 15–20
20. Eviatar A (1978) Tragal perichondrium and cartilage in reconstructive ear surgery. *Laryngoscope* 88(S11):1–23
21. Adkins WY (1990) Composite autograft of tympanoplasty and tympanomastoid surgery. *Laryngoscope* 100:244–247
22. Amedee RG, Mann WJ, Riechelmann H (1989) Cartilage palisade tympanoplasty. *Am J Otol* 10:447–450
23. Duckert LG, Mueller J, Makielski KH, Helms J (1995) Composite autograft “shield” reconstruction of remnant tympanic membranes. *Am J Otol* 16:21–26
24. Dornhoffer JL (1997) Hearing results with cartilage tympanoplasty. *Laryngoscope* 107:1094–1099
25. Gerber MJ, Mason JC, Lambert PR (2000) Hearing results after primary cartilage tympanoplasty. *Laryngoscope* 110:1994–1999
26. Donhoffer JL (2000) Surgical management of atelactatic ear. *Am J Otol* 21:315–321
27. Onal K, Uguz MZ, Kazikdas KC, Gursoy ST, Gokce H (2005) A multivariate analysis of ontological, surgical and patient related factors in determining success in myringoplasty. *Clin Otolaryngol* 30:115–120
28. Pinar E, Sadullahoglu K, Calli C, Oncel S (2008) Evaluation of prognostic factors and middle ear risk index in tympanoplasty. *Otolaryngol Head Neck Surg* 139:386–390
29. Indorewala S (2002) Dimensional stability of the free fascia grafts: an animal experiment. *Laryngoscope* 112:727–730
30. Cabra J, Monoux A (2010) Efficacy of cartilage palisade tympanoplasty: randomized controlled trial. *Otol Neurotol* 31:589–595
31. Tos M (2008) Cartilage tympanoplasty methods: proposal of classification. *Otolaryngol Head Neck Surg* 139(6):747–758
32. Zehnert T, Huttenbrink KB, Munbe D, Bornitz M (2000) Experimental investigations of the use of cartilage in tympanic membrane reconstruction. *Am J Otol* 21:322–328
33. Kerr AG, Byrne JE, Smyth GD (1973) Cartilage homograft in the middle ear: a long term histologic study. *J Laryngol Otol* 87:1193–1199
34. Don A, Linthicum FH Jr (1975) The fate of cartilage grafts for ossicular reconstruction in tympanoplasty. *Ann Otol Rhinol Laryngol* 84(2):187–191
35. Iwanaga M, Mori H, Yamamoto E, Toda Y, Fukumoto M (1986) The fate of homologous nasal septal cartilages in tympanoplasty. *Acta Otolaryngol* 101(3–4):306–313
36. Frootko NJ (1987) Reconstruction of the ear. In: Booth JB, Kerr AG (eds) *Scott Brown’s otolaryngology*, 5th edn. Butterworth, London, pp 238–263