



Dr Ahila's Endoscopic Ear Surgery Chisel and Mallet

Nagalingeswaran Ahilasamy¹ ·
Rajendran Dinesh Kumar² · R. Kavyashree² ·
Ibrahim Ayub²

Received: 12 December 2022 / Accepted: 23 February 2023
© Association of Otolaryngologists of India 2023

Abstract Endoscopic Ear surgery is evolving day by day and there is need for constant improvement in terms of instrumentation with efficient, quicker, with clear bloodless surgical field and good postoperative outcome and results. The application of Dr Ahila's Endoscopic Ear Surgery Chisel and Mallet are presented. This innovation will provide limited and adequate bone removal in a faster way than drill in endoscopic mastoidectomy and stapedotomy surgeries. Surgical instruments represent a major financial asset to the health care facilities. The use of Dr Ahila's Endoscopic Ear Surgery straight 1 mm or 2 mm Chisel and Mallet is presented. Dr Ahila's Endoscopic Ear Surgery Chisel and Mallet, this innovation will provide faster bone removal than drill or curette without bone dust formation, fogging, irrigation in Endoscopic mastoidectomy and stapedotomy. This instrument is essential to avoid costly replacement, surgeon satisfaction, reduce cost and delays in the operating room and in safe and trained hands enhance patient safety.

Supplementary Information The online version contains supplementary material available at <https://doi.org/10.1007/s12070-023-03629-0>.

✉ Rajendran Dinesh Kumar
dinuraj1186@gmail.com

Nagalingeswaran Ahilasamy
nahilasamy@yahoo.com

R. Kavyashree
kavya531990@gmail.com

Ibrahim Ayub
ayub.ebrahim02@gmail.com

¹ Ahilasamy ENT Centre, Chennai, Tamil Nadu 600 042, India

² Department of ENT and Head-Neck Surgery,
Rajarajeswari Medical College and Hospital, Bengaluru,
Karnataka 560074, India

Keywords Endoscope · Ear surgery · Mastoidectomy · Stapedotomy · Chisel · Mallet

Introduction

Endoscopic Ear surgery is evolving day by day and there is need for constant improvement in terms of instrumentation with efficient, quicker, with clear bloodless surgical field and good postoperative outcome and results. The application of Dr Ahila's Endoscopic Ear surgery Chisel and Mallet are presented.

This innovation will provide limited and adequate bone removal by following the disease process, in bone removal in mastoidectomy, avoiding bone dust formation during drilling and much faster than with time consuming drilling. In stapedotomy too it helps in faster posterior superior bony overhang removal than curetting. Surgical instruments represent a major financial asset to the health care facilities. This instrument is essential to avoid costly replacement, surgeon satisfaction, reduce cost and delays in the operating room and in safe and trained hands enhance patient safety.

Author's Perspective: The Need and Idea

While performing endoscopic ear surgery specially customized Endoscopic Ear surgery instruments of size 1 mm, 2 mm Chisel and Mallet [1].

Procedure: Under Local Anaesthesia, Sedation, Postaural infiltration with Injection 0.5% ropivacaine with adrenaline for ear canal infiltration and temporal area to harvest temporalis fascia by Endoscopic method. Initially canal infiltration in the ear canal in 2 points in posterior and anterior wall of the ear canal. Temporalis fascia graft is harvested.

Endoscopic (3 mm, 0 Degree Endoscope) Transcanal tympanomeatal flap elevation from the bony annulus using Dr.Ahila's diathermy round knife. Later Using 1 mm or 2 mm straight Endo ear chisel alternatively with small mallet to chisel the Posterior and Superior bony wall following the cholesteatoma disease. Endoscopic curette to remove thin bone & smoothen the cavity (Figs. 1, 2, 3) in Endoscopic Mastoidectomy.

Dr Ahila's Endoscopic Ear Surgery Chisel is straight 1 mm, 2 mm instrument used with a mallet primarily for



Fig. 1 Dr Ahila's Endoscopic Ear Chisel 1 mm, 2 mm and Mallet

precise bone removal for limited exposure in endoscopic ear surgery. In endoscopic stapedectomy it can be used to remove posterior bony overhang instead of curetting or drilling the bone.

For microscopic ear surgery microdrill is ideal, as bony removal and saucerization of the mastoid cavity is more when compared to endoscopic ear surgery which has limited bone removal, the disease clearance from the middle ear cleft is performed using micro-ear instruments and suction. The overall result is a small mastoid cavity which is later reconstructed by cartilage over the posterior canal wall thus avoiding mastoid cavity problems.

In Endoscopic Stapedectomy after tympanomeatal flap elevation for the posterosuperior bony overhang removal instead of curetting or drilling bone with chisel is much faster.

Why use Chisel and Mallet?

1. While drilling with one hand method as in Endoscopic ear surgery, there is splatter of Bone dust which requires regular irrigation and suctioning.
2. As the endoscopic ear surgery requires minimal bone removal which can be addressed specially designed Endoscopic chisel and mallet.
3. Frequent fogging of the endoscope can be avoided.
4. During COVID-19 Pandemic, Excessive use of micro drill resulting in bone dust aerosol generation which is a source of potential transmissibility of SARS-CoV-2

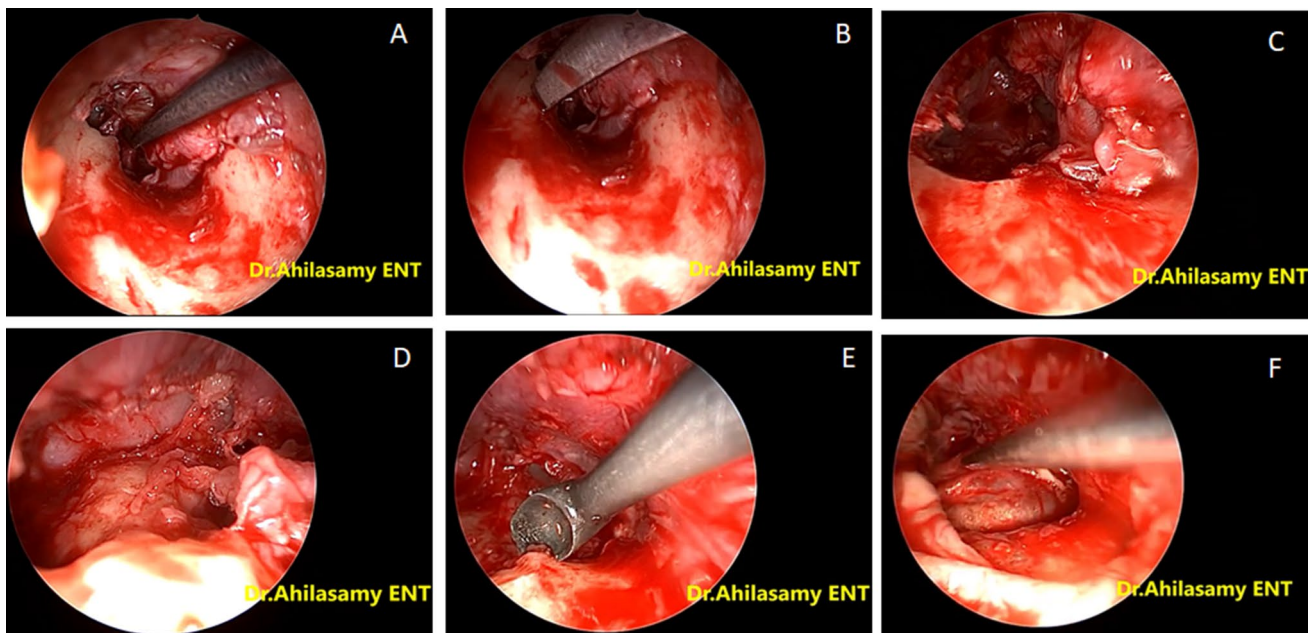


Fig. 2 Endoscopic View of Use of Dr Ahila's Endoscopic Ear Chisel 1 mm, 2 mm in mastoidectomy surgery

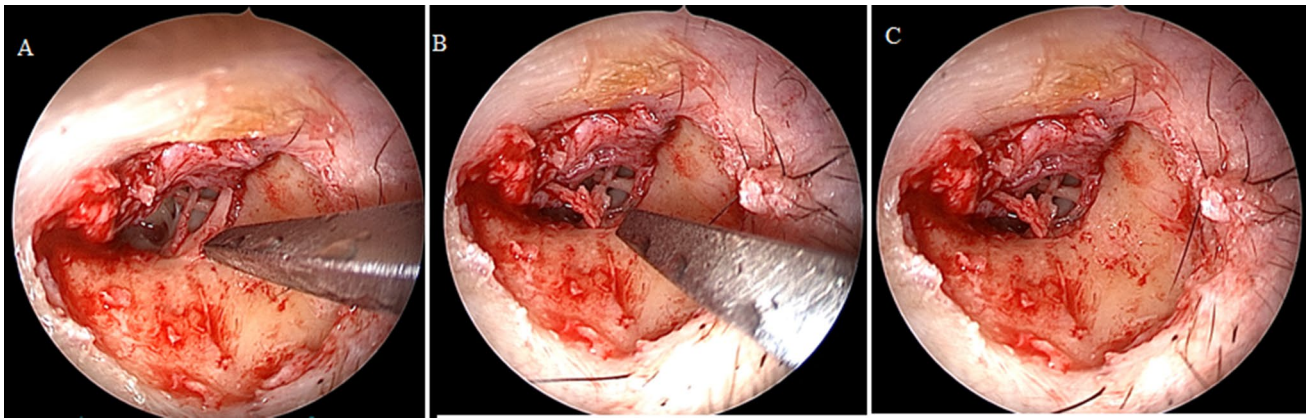


Fig. 3 Endoscopic View of Use of Dr Ahila's Endoscopic Ear Chisel 1 mm, 2 mm in stapedotomy surgery

virus between staff and patients in both directions. This led to complete interruption in routine ear surgery services in most parts of the world.

5. For Bony over hang removal for Middle ear surgery (Stapedotomy and Chronic Otitis media)
6. In experienced Hands controlled bone removal can be performed with ease, efficiency and quickly. With fine hands and good control this can be performed.
7. Limited and adequate bone removal by following the disease process, avoiding mastoid cavity problem due to extensive mastoid bone removal.
8. Working with Chisel and Mallet is faster than using drill or curette.
9. For removal of External auditory canal exostoses.

Risk with the Above Methods?

1. Injury to middle ear ossicles, Facial nerve, Tegmen injury, Chorda tympani injury.
2. Patient may at risk of developing loss of hearing, Loss of taste sensation in the anterior 2/3rd of the tongue, Facial palsy and CSF otorrhea.

Alternatively—Endoscopic Ear Drill / Curette can be used which also have the same complications.

Dimensions of Instrument: Straight instruments of size 1 mm, 2 mm Chisel and Mallet.

Sterilization

Sterilization of the instrument can be done by with an enzymatic cleaner for contact time of 10–15 min, gentle cleaning of the tip of the instrument with brushes/small soft bristle tooth brush and then flushed with RO water or clean tap

water. Then dried and sterilized by autoclaving or ETO gas sterilization.

Discussion

Three instrumental periods in the history of mastoidectomy surgery includes the trepan period, the chisel and gouge period, and the electrical drill period [2].

The first surgical opening of the mastoid was performed by Petit in 1736 with a trepanation system. More than one and a half centuries later, in 1873, Schwartze codified the operation using chisels and gouges. At the end of the nineteenth century, Macewen introduced the electrical dental burr for mastoid surgery, but it remained largely unrecognised. At the beginning of the 1950s, the systematic use of the microscope in ear surgery allowed generalised use of the drill and improvement of the suction-irrigation system [2].

In a study published by Barrett et al. and Kozin et al. the use of a microchisel is a safe and efficient technique for the removal of EAC exostoses, although we acknowledge that a drill is often necessary as an adjunct in difficult cases [3, 4].

In a study published by Pou, the author follows a technique in chronic ear with cholesteatoma, bone graft is taken from the mastoid process with a 4 mm curved rhinoplasty chisel and mallet, before mastoidectomy. The Bony graft is cut fairly thin so that it curls similar to the contour of the ear canal, this method reduced postoperative retraction pockets [5].

Soni et al. Referring ancient practices like above in this COVID pandemic era may prove an important tool in addressing surgical urgencies while combating transmission risks at the same time, the microchisel and mallet found its use again for ear surgery [6].

Drills have multiple advantages, but during COVID pandemic it is source of high speed aerosols putting surgeons and other OR personnel at risk of serious infections. Chisel

and mallet can be used to perform mastoid exploration, stapedotomy and removal of bony exostoses of external auditory canal avoiding aerosols generation with adequate disease clearance.

Any Surgery involving the middle ear and mastoid, due to their continuity with the upper aerodigestive tract, puts health care workers at high risk for COVID-19 transmission. Such surgery may need to be deferred, but when necessary personal protective equipment use is advised and the use of high-speed drills to be avoided. Using endoscopic chisel and mallet decreases the amount of aerosol generation and hence decreasing risk of transmission of COVID 19.

Conclusion

Surgical instruments represent a major financial asset to the healthcare facility. Careful attention to care, handling and sterilization is essential to avoid costly replacements, surgeon satisfaction, reduce costs and delays in the operating room and enhance patient safety. Dr Ahila's Endoscopic Ear Surgery Chisel and Mallet, this innovation will provide faster bone removal than drill or curette without bone dust formation, fogging, irrigation in Endoscopic mastoidectomy and stapedotomy. It is hoped that this manuscript will contribute to such recognition.

Author Contributions AN: Performed surgery, prepared the manuscript and patient preoperative and postoperative management and follow up. RDK: Review of the Instrument, Final editing the manuscript. KR: Video Editing, Description of the Instruments. IA: Legends to Figures.

Declarations

Conflict of interest None declared.

Informed Consent Informed consent was obtained from individual participant included in the study.

Ethical Approval All procedures performed in studies involving human participants were in accordance with the ethical standards of the institutional and/or national research committee and with the 1964 Helsinki declaration and its later amendments or comparable ethical standards.

References

1. Kurien G, Greeff K, Gomaa N et al (2013) Mastoidectomy and mastoid obliteration with autologous bone graft: a quality of life study. *J Otolaryngol Head Neck Surg* 42:49. <https://doi.org/10.1186/1916-0216-42-49>
2. Mudry A (2009) History of instruments used for mastoidectomy. *J Laryngol Otol* 123(6):583–589. <https://doi.org/10.1017/S002215109004484>
3. Barrett G, Ronan N, Cowan E, Flanagan P (2015) To drill or to chisel? A long-term follow-up study of 92 exostectomy procedures in the UK. *Laryngoscope* 125(2):453–456. <https://doi.org/10.1002/lary.24849>
4. Kozin ED, Remenschneider AK, Shah PV, Reardon E, Lee DJ (2015) Endoscopic transcanal removal of symptomatic external auditory canal exostoses. *Am J Otolaryngol* 36(2):283–286. <https://doi.org/10.1016/j.amjoto.2014.10.018>
5. Pou JW (1977) Reconstruction of bony canal with autogenous bone graft. *Laryngoscope* 87:1826–1832. <https://doi.org/10.1002/lary.1977.87.11.1826>
6. Soni S, Shrivastava N, Bharti B, Kumar V, Prakash R, Suneha S, Singh SK, Bhavana K (2022) Awareness of an primitive art for treating Otological diseases in present Covid-19 scenario: need of the hour. *Indian J Otolaryngol Head Neck Surg* 74:449–452. <https://doi.org/10.1007/s12070-020-02232-x>

Publisher's Note Springer Nature remains neutral with regard to jurisdictional claims in published maps and institutional affiliations.

Springer Nature or its licensor (e.g. a society or other partner) holds exclusive rights to this article under a publishing agreement with the author(s) or other rightsholder(s); author self-archiving of the accepted manuscript version of this article is solely governed by the terms of such publishing agreement and applicable law.