

# PAPILLARY THYROID CARCINOMA IN A THYROGLOSSAL CYST

Ravi Ramalingam<sup>1</sup>, K. K. Ramalingam<sup>2</sup>, A. V. Ramesh<sup>3</sup>, S. Mahesh Prabhu<sup>4</sup>,  
Manu Vergis<sup>5</sup>, N. Ahilasamy<sup>6</sup>

**ABSTRACT :** *The incidence of Papillary Thyroid Carcinoma in a Thyroglossal Cyst is rare. Only about 160 cases have been reported in the last 85 years. We report a case of Thyroglossal Cyst who underwent Sistrunk's Operation. The Cyst was reported to contain a focus of papillary thyroid carcinoma. In the absence of metastases in thyroid gland and neck nodes, only thyroid suppression with Thyroxine was given. After 1 year of follow-up there are no metastases. The importance of Sistrunk's operation lies not only in complete removal of Thyroglossal Cyst but also in management of small foci of Papillary thyroid Carcinoma.*

**Key Words:** *Thyroglossal cyst, Papillary carcinoma*

## INTRODUCTION

Thyroglossal cyst is a common congenital neck mass resulting from persistence and dilatation of an epithelial tract formed during migration of thyroid during embryogenesis. Thyroid tissue is present in the cyst wall in more than 60% of cases (Maran,1997). We report a rare case of Thyroglossal cyst in which the thyroid tissue in cyst wall showed Papillary carcinoma.

## CASE REPORT

A 22 year old female presented to our centre with complaints of a painless swelling in the neck which has been growing slowly in size over last 3 months. On examination there was a 2cms oval, cystic swelling in the subhyoid region to the left of midline . The swelling moved with deglutition and with protrusion of the tongue .X-RAY neck lateral view was normal. Thyroid Function Tests.i.e.T3,T4,TSH and Ultrasonogram of Thyroid gland were normal . I-131 scan did not reveal any cold nodules in the thyroid gland.(Fig.I) There was no uptake of radioactive iodine by the swelling.A diagnosis of thyroglossal cyst was made and the patient underwent excision of the cystic swelling by Sistrunk's operation. The cyst, the body of hyoid and a cuff of central base of tongue were removed.

The histological examination of the swelling revealed a focus of Papillary Carcinoma of Thyroid (Fig. II).The cyst wall had cuboidal lining which was resting on some

granulation tissue and a fibromuscular wall with adipose tissue. One of the fragments showed a papillary lesion composed of true papillae lined by cells with overlapping nuclei, nuclear clearing, intranuclear cytoplasmic inclusions and nuclear grooves.The wall adjacent to this papillary lesion shows dilated cyst with colloid and pigmented macrophages.The patient was put on suppressive treatment of Tab Thyroxine 0.2mg OD. After 1 year patient is asymptomatic. Thyroid function tests and thyroid scan were normal . There was no evidence of secondaries in the neck.

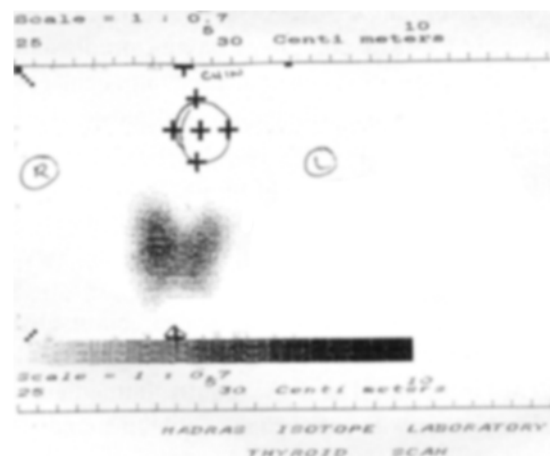


Fig. I : Preoperative thyroid scan showing thyroid in the normal position with no cold nodules. There is no uptake by the thyroglossal cyst.

<sup>1</sup>Consultant ENT Surgeon, <sup>2</sup>Director & Senior Consultant ENT Surgeon, K.K.R. ENT Hospital & Research Institute & Chinnammal ENT Hospital, <sup>3,4,5</sup>Registrars, K.K.R. ENT Hospital & Research Institute, <sup>6</sup>Consultant ENT Surgeon, Chinnammal ENT Hospital, Noombal, Chennai

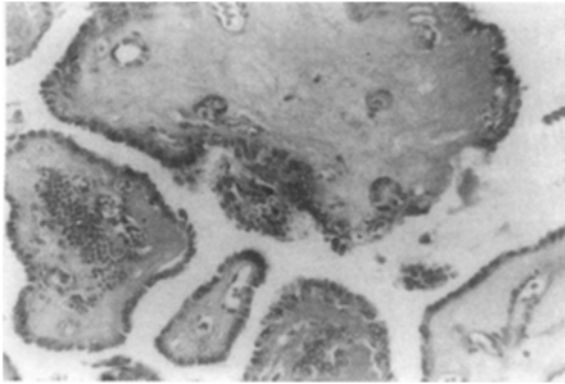


Fig. II : Photomicrograph showing papillary fronds lined by cells with crowded, overlapping nuclei showing prominent nuclear clearing (orphan-Annie Nuclei) [ H & E x 200 ]

## DISCUSSION

Thyroglossal duct cyst is a common congenital neck mass. However less than 1% of the cysts show malignant changes (O'Connell et.al.,1998). In the past 85 years, about 160 cases have been reported of which less than 10 are in children (Yoo et.al.,1998)- an indication that perhaps the malignancy arises denovo in the thyroid tissue of the thyroglossal remnants. Papillary Carcinoma is the most common . Isolated cases of follicular carcinoma, hurthle cell carcinoma, squamous cell carcinoma and insular carcinoma are also reported. Foci of papillary carcinoma in thyroid gland were seen in 4 out of a series of 10 cases of thyroglossal cyst carcinoma with only 1 tumour larger than 1 cm. Incidence of cervical metastases have also been reported (Micolli et.al., 1998).

Most commonly the diagnosis of papillary carcinoma in thyroglossal cyst is made postoperatively. With improved techniques of FNAC , it has been possible to diagnose about 20 cases preoperatively (Yang et.al.,2000). Thorough clinical evaluation to rule out metastases in the thyroid gland and neck by way of Ultrasonography of neck and thyroid gland is a must before surgery. Scintiscanning would reveal the presence of normal thyroid gland and any cold nodules therein.

Biological behavior of papillary carcinoma of thyroglossal cyst and thyroid gland are similar. Microscopic focus of papillary carcinoma in a thyroglossal cyst without cystwall invasion can be managed by Sistrunk's operation alone. Postoperative thyroid suppression with thyroxine is advocated by some. More extensive involvement of the cyst and thyroid gland would require a total thyroidectomy (Kennedy et.al.,1998). Cervical metastases would necessitate a radical neck dissection .Recurrences are rare after adequate surgery and can be managed with radioiodine and radiotherapy. The prognosis is excellent in patients with papillary carcinoma in thyroglossal cyst as compared to other rarer types.

## REFERENCES

1. AGD Maran (1997) : Benign diseases of neck. In: Alan G Kerr, John Hibberts, eds. Scott Brown's Otolaryngology. 6<sup>th</sup> edn. Oxford : Butterworth -Heinemann, 5 / 16 / 2
2. O'Connell M, Grixiti M, Harmer C. (1998) : Thyroglossal duct carcinoma : presentation and management. Clinical Oncology (Royal College of Radiologists) ; 10 (3) : 186 -190.
3. Yoo KS, Chengazi VU, O'Mara RE. (1998) : Thyroglossal duct cyst with papillary carcinoma in an 11 year old girl .J Paediatric Surgery 33 (5) : 745 - 6
4. Micolli P, Pacini F, Basolo S, Iaconni P, Puccini M ,Pinchera A. (1998) : Thyroid carcinoma in a thyroglossal duct cyst: Tumor resection alone or a total thyroidectomy? Ann de Chirurgie ; 52 (5) : 452 - 4
5. Yang YJ, Hagher S, Wanamaker JR, Powers CN. (2000) : Diagnosis of papillary carcinoma in a thyroglossal duct cyst by fine needle aspiration biopsy. Archives of Pathology and Laboratory Medicine ; 124 (1) : 139-42
6. Kennedy TL, Whitaker M, Wadih G. (1998) : Thyroglossal duct carcinoma : a rational approach to management. Laryngoscope ; 108 : 1154-8

## Address for Correspondence :

Dr. Ravi Ramalingam  
K. K. R. ENT Hospital & Research Institute,  
827, Poonamallee High Road,  
Kilpauk, Chennai - 600 010.